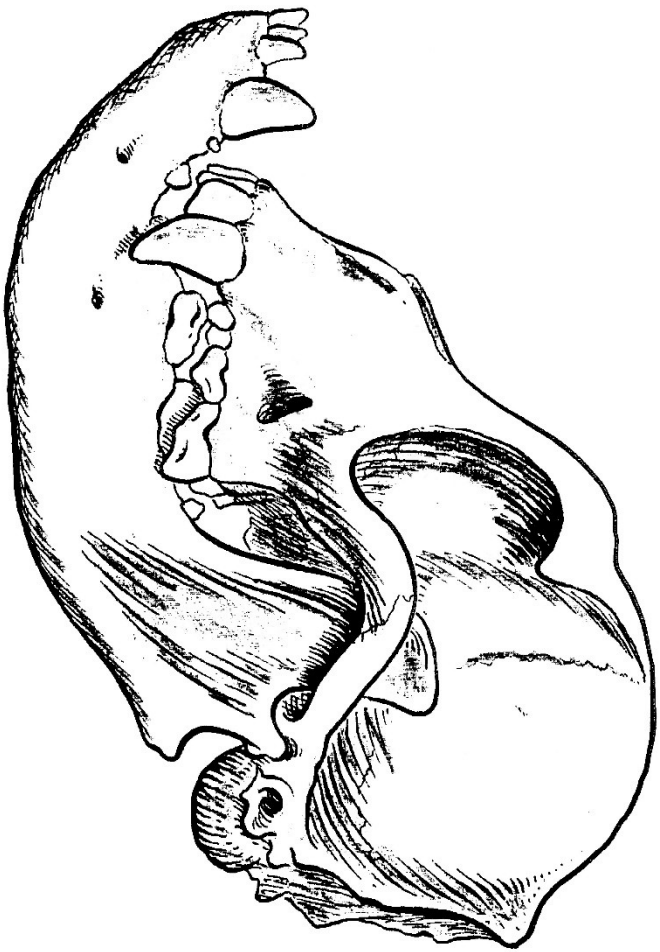


DENTAL ANATOMY



PETER EMILY D.D.S., A.V.D., A.V.D.C.

Glossary of Dental Terminology and Tooth Anatomy

The following list of dental definitions and terms include those that are necessary for everyday dental usage and those that may occasionally be encountered. The most important have an asterisk.

- Abrasion:** the wear of teeth acting upon one another during mastication (chewing).
- Alignment*:** the position of the teeth in the arch or mouth in relation to each other.
- Alveolar bone:** the compact bone that composed the alveolus (tooth socket).
- Alveolus:** the bony socket of a tooth.
- Apex:** the point of cone-shaped object, such as the root of the tooth. The root tip or end.
- Apical foramen:** the opening in the root of a tooth allowing for the passage of the vessels and nerves composing the dental pulp.
- Asymmetrical dental arch*:** that which is not symmetrical, as seen in wry bites.
- Axle:** the central length-wise line through the crown and the root.
- Bifurcation:** the division into two parts or branches, as any two roots of a tooth.
- Bite*:** the term should be reserved for the act of incision of a morsel of food and in connection with discussions of the amount of pressure developed in closing the jaws. *In canine terminology* it is the relationship of upper to lower arch; the relationship of the upper teeth to the lower teeth.
- Calculus*:** the hard mineralized deposit attached to the teeth.
- Carnassial teeth*:** the upper fourth premolar and lower first molar comprise the carnassial teeth. These come into sharp action when the dog closes or bites, providing a shearing or cutting action to cut through sinews and tough parts of meat and bone.
- Cheek teeth:** in canine dentistry, the teeth to the rear or in back of the canine; comprised of molars and premolars.
- Cingulum:** refers to the tongue side lobe of incisor teeth.
- Crossbite*:** one or more of the upper teeth are in reverse position to the lower teeth; upper tooth or teeth on the inside of the lower teeth.
- Crown:** that part of the tooth covered by enamel.
- Cusp:** notably pointed or rounded eminence on or near the chewing surface of a tooth.
- Dentiri*:** the main component of the tooth. It is yellowish in color and is covered by the enamel and cementum. It is harder than bone but more porous and softer than enamel.
- Freeway space:** the space between the upper and lower opposing teeth when the jaw is suspended in a resting position.
- Frenum:** a mucous membrane which connects two parts, one more or less movable, and serves to check the movement of this part, i.e., tongue to the floor of the mouth.
- Frenectomy:** the excision of the frenum.
- Furcal:** the forked or branching as the roots of multirooted teeth.
- Fused teeth*:** two teeth that are joined at the dentin and enamel, counted as two teeth.
- Fusion:** the union of two adjacent tooth buds. Fusion usually involves the crowns only and are united through the dentin and enamel; two separate root systems and counted as two separate teeth.
- Gemination, double crown, twinning*:** the splitting of a single tooth germ. It usually has a single root with a common pulp cavity. *These are counted as one tooth.*
- Gingiva gum:** that part of the gum tissue and mucous membrane which immediately surrounds the tooth and is continuous with its periodontal ligament (tooth supporting fibers) and with the mucosal tissues of the mouth.
- Gingival papillae:** the portion of the gum tissue between the teeth.
- Gingival sulcus:** the extremely important small moat surrounding each tooth formed by the gingiva (gum). This small area is the most biologically active area in the mouth.
- Gingivectomy:** the excision of the soft tissue wall to eliminate gingival pockets.
- Gingivitis:** the inflammation of the gingiva.
- Hypoplasia, (enamel):** teeth with band ridges or pitted areas of discolored enamel, usually caused by a disturbance during enamel formation; example, a high fever or infection.
- Intermaxillary*:** between the jaws, from one jaw to the other.
- Macrodonia:** large teeth.
- Mandible*:** the lower jaw.
- Maxilla*:** the upper jaw.
- Midline:** that portion toward or situated in the middle.
- Microdonia:** small teeth.
- Missing teeth*:** the absence of one or more teeth that are normally found in the mouth. Most frequently the premolars, followed in frequency by the incisors and then the molars. This is generally believed to be an autosomal recessive fault. It can become a dominant fault if dogs with missing teeth are bred to those with missing teeth.
- Open bite*:** the condition when the molar and premolar teeth are in contact and the incisor teeth are not. There is an open space between the edges of upper and lower incisors. This space between the incisors can vary from a slight amount to as much as 2 cm. (3/4"). This condition can exist on one side only as seen in a wry bite.
- Overbite*:** vertical overlapping of the lower incisors by the upper incisors.
- Periapical:** anything situated or occurring around the apex or tip of a tooth.
- Periodontium:** the supporting tissues adjacent to the teeth.
- Pulp*:** the inside the center of the tooth (pulp canal) and is filled with nerves, blood vessels and connective tissue. These tissues enter from the body through the end of the tooth.
- Recession:** the loss of part or all of the gingiva over the root of a tooth.
- Root (dental):** that portion of the tooth below the crown that extends into the supportive bone of the dental arches. It comprises approximately two-thirds of the tooth and contains all the vital components of the tooth, i.e., nerves and vessels.
- Root canal*:** the central cavity of the root through which the vital structures (nerves, arterioles, venules) pass into the pulp chamber.
- Root planning:** smoothing of roughened root surfaces by the use of scalers and curettes.
- Ruga:** the irregular ridges in the mucous membrane covering the front part of the hard palate.
- Scissor bite*:** the total lingual cross-bite of the lower teeth, with the lower teeth completely contained within the upper dental arch in habitual closure of the teeth.
- Supernumerary (extra teeth)*:** an abnormal number of teeth that may not resemble any normal teeth in size or shape. *Example:* two upper first premolars.
- Vestibule:** the portion of the oral cavity which lies between the teeth and gums and between the lips and cheeks.

—P.E.

SCISSOR BITE

In the scissor bite, the upper central incisors (the two middle teeth) overlap the facial (outside) surfaces of the two lower central incisors and a small portion of the mesial (inside) surfaces of the intermediate lateral incisors.

The incisal (biting) edges of the lower central incisors contact the cingulum of the upper central incisors, (Fig. 1). The lower lateral incisors rests on the small distal (outside) cusp, (Fig. 1) of the upper intermediate lateral incisor, and on the mesial (Inside) cusp of the upper lateral incisor.

The lower canine should interdigitate in the space between the upper lateral incisor and canine teeth. There should be no contact between the lower canine and either of the upper teeth.

The lower premolars are anterior (to the front) of their counterparts, I.E., lower first premolar in the front of the upper first premolar, lower second premolar in the front of the upper second premolar, etc. The upper fourth premolar covers the large front cusp of the lower first molar. The lower second molar will occlude (bite) with the rear one-half of the upper second molar and most of the occlusal (biting) surface of the upper second molar.

The lower third molar may or may not occlude with the rear cusp of the upper second molar. Any deviation from the above definition is a deviation from the normal.

The degree of deviation and the direction, I.E., forward or rearward shift of the mandible (lower Jaw), is the determining factor as to overshoot or undershot bites.

The key to occlusion or the type of bite is seen in the relationship of the maxilla to the mandible (upper jaw to the lower jaw) in the premolar teeth.

This key is found in the alignment of the premolars and molars. The upper first premolar lines up to a slot between the lower first premolar and the lower second premolar. The upper second premolar lines up in a slot between the lower second premolar and the third premolar, and so forth, to form a "pinking shear" effect. (Fig. 2).

The condition often times exists when front teeth can be seen to be in scissor occlusion or bite, but the premolar and molars are in overshoot or undershot position as seen when the upper premolars oppose the lower premolars. Example: the upper first premolar opposes the lower second premolar in an undershot condition, but opposes the lower first premolar in an overshoot condition (Fig.3 & Fig.4). When this occurs, the dog is still overshoot or undershot regardless of the relationship of the front teeth.

The genetic potential to produce this type of bite is still present. The offspring could show the same relationship as the sire and/or dame, or have through the inherited predisposition to overshot or undershot condition, complete overshot or undershot bite.

WRY BITE

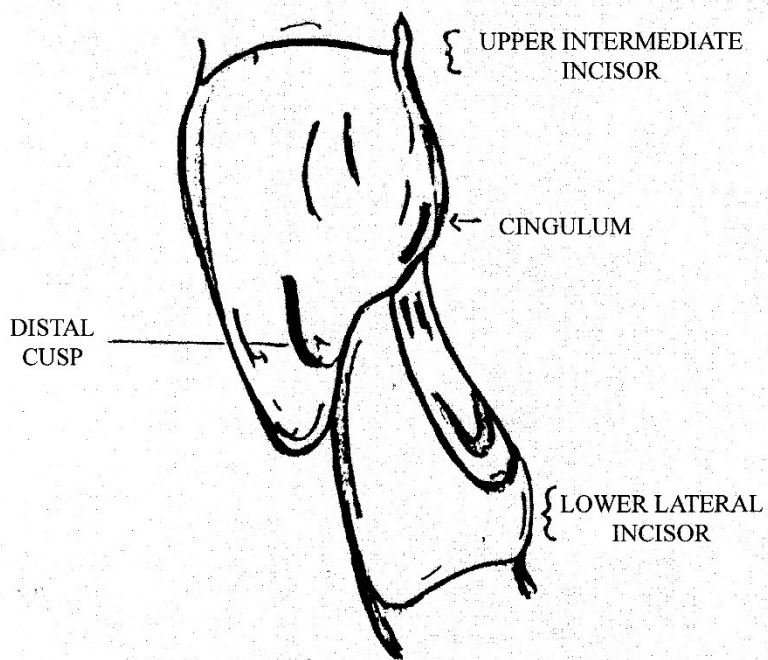
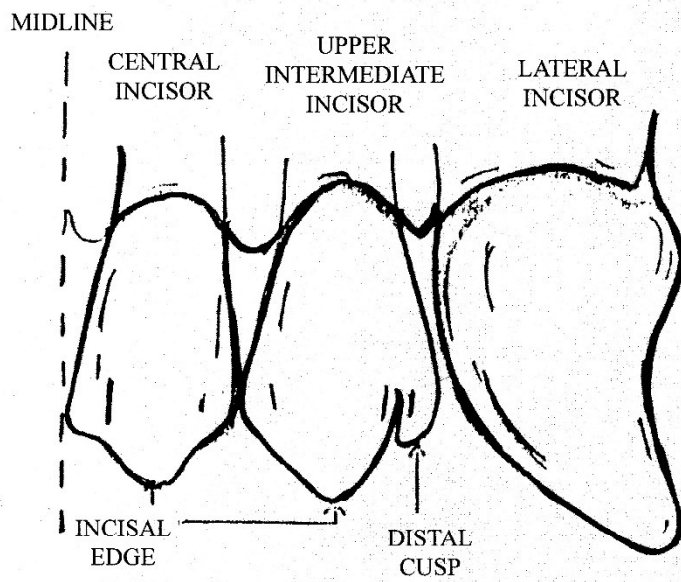
In the wry bite, the upper and lower dental arches or halves do not develop equally. This unequal development will often show one side to be in a normal bite scissor bite, and the other side open and undershot at the same time (by open we mean the vertical dimension or space between the upper and lower teeth will be greater on the undershot side).

There is a deviation or deflection of the upper jaw to one side, usually the undershot and open side. This is seen by tracing the midline of the head from the top of the skull through the midpoint between the eyes and down the muzzle through the nose. Oral examination shows this deflection of the midline in the alignment of the front teeth. The midline of the lower front teeth will not be in line with the midline of the upper front teeth but will be deviated away from the effected or undershot side.

The wry mouth can effect vertical and lateral growth of one side if the head thereby adding to the lopsided effect by the appearance of one side of the head to be larger than the other in some cases. (Fig. 5).

The amount of unilateral or one sided head growth, prognathism, midline deviation and or lopsided appearances is directly proportional or related to the degree of the wry fault.

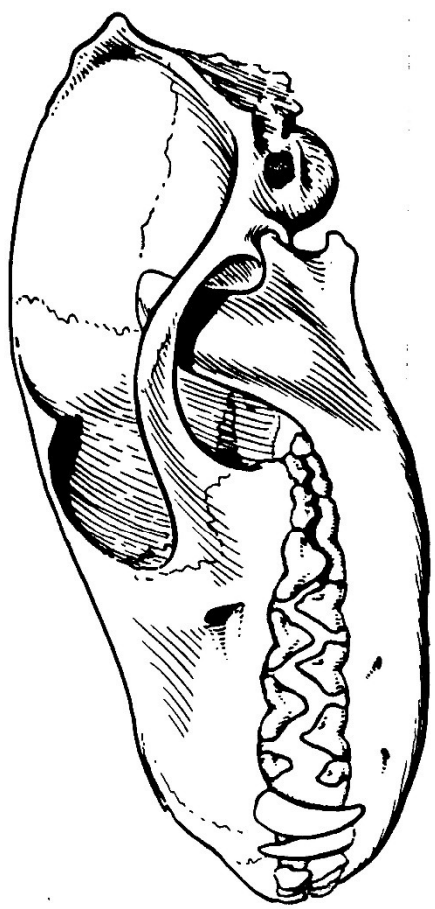
Peter P. Emily, D.D.S., A.V.D., A.V.D.C.



PROPER OCCLUSION AND ALIGNMENT OF CLOSED POSITION OF FRONT TEETH IN SCISSOR BITE

FIG 1

Dr. Peter P Emily



NORMAL

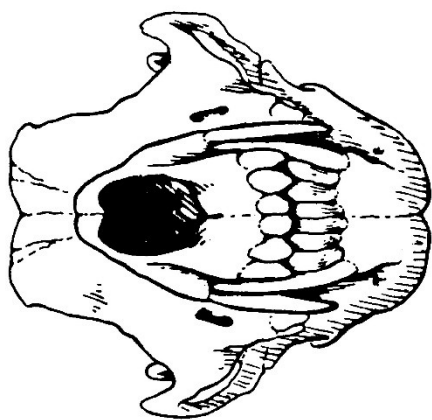


FIG 2

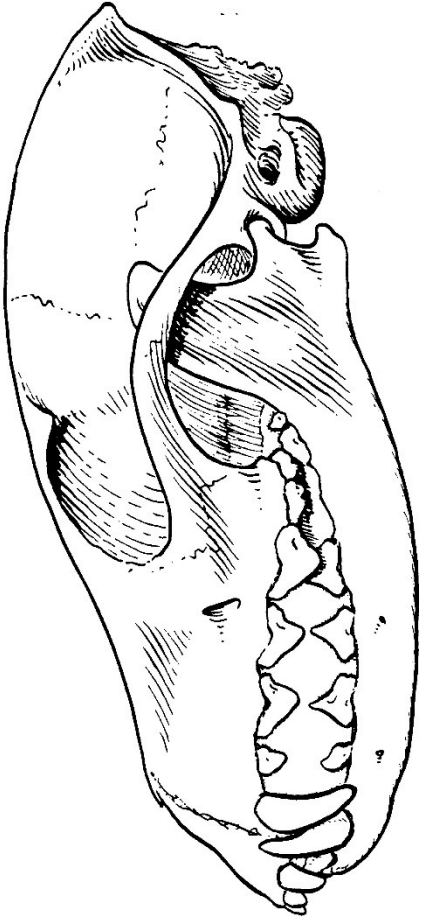


FIG 3 OVERSHOT

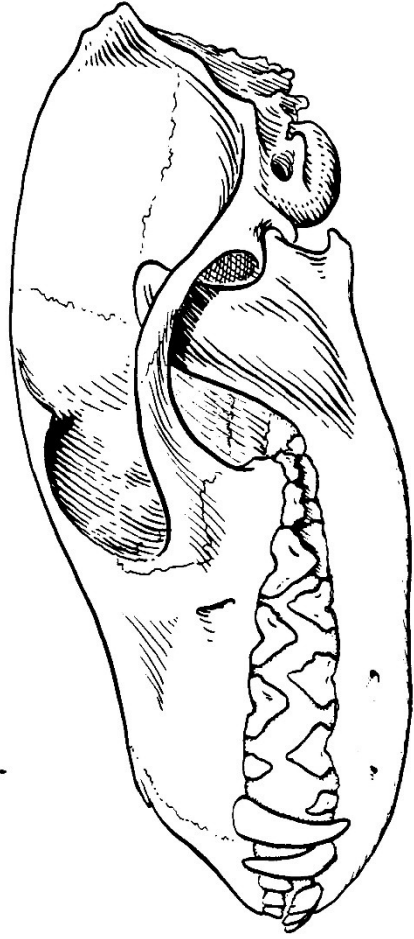
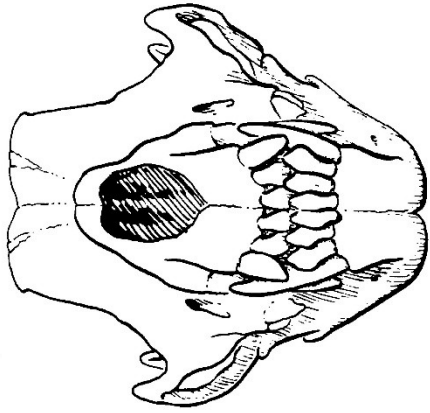
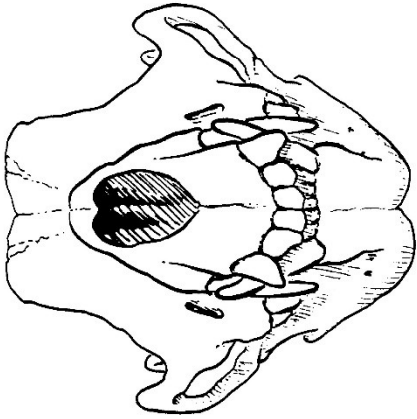


FIG 4 UNDERSHOT



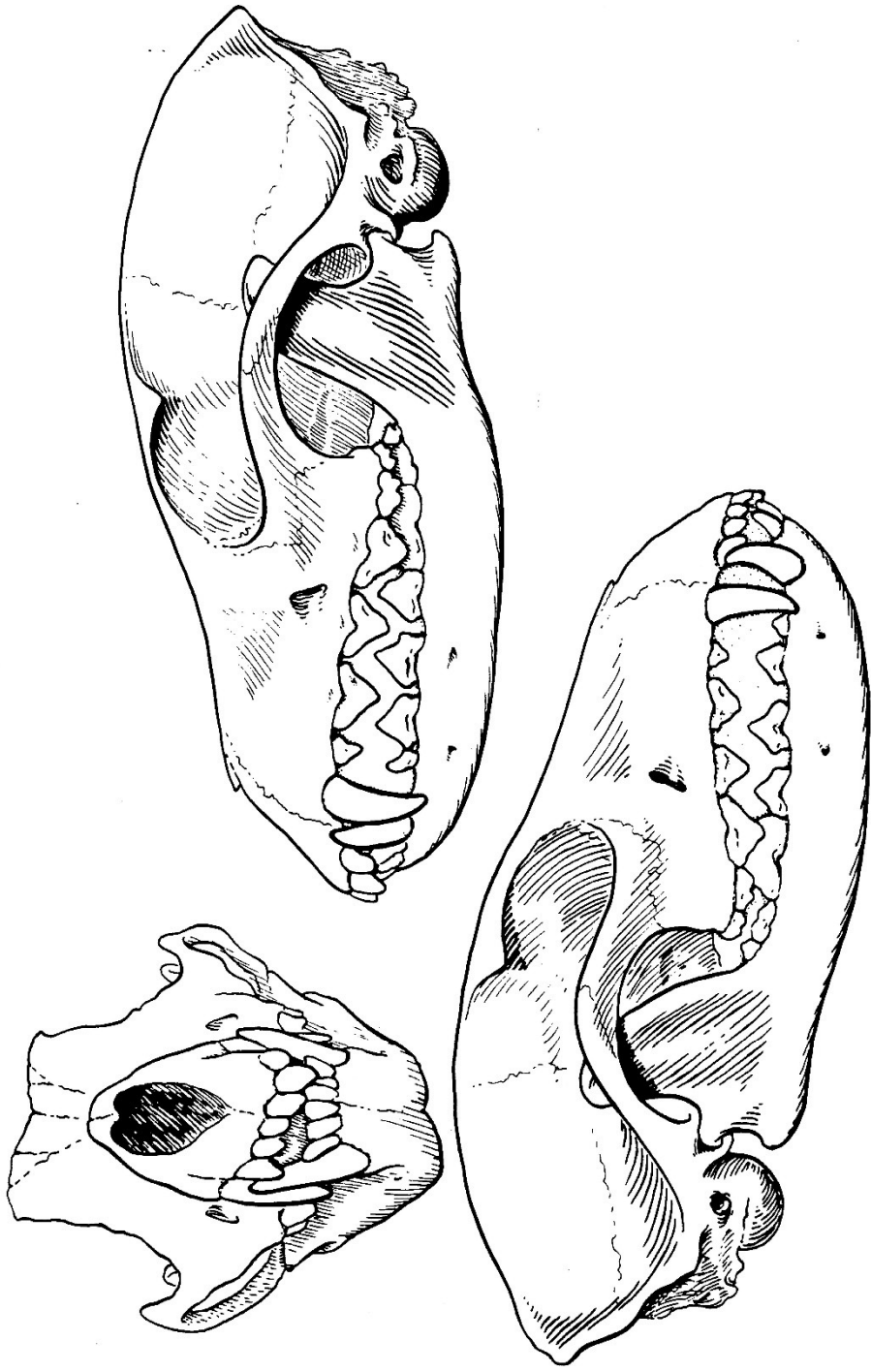
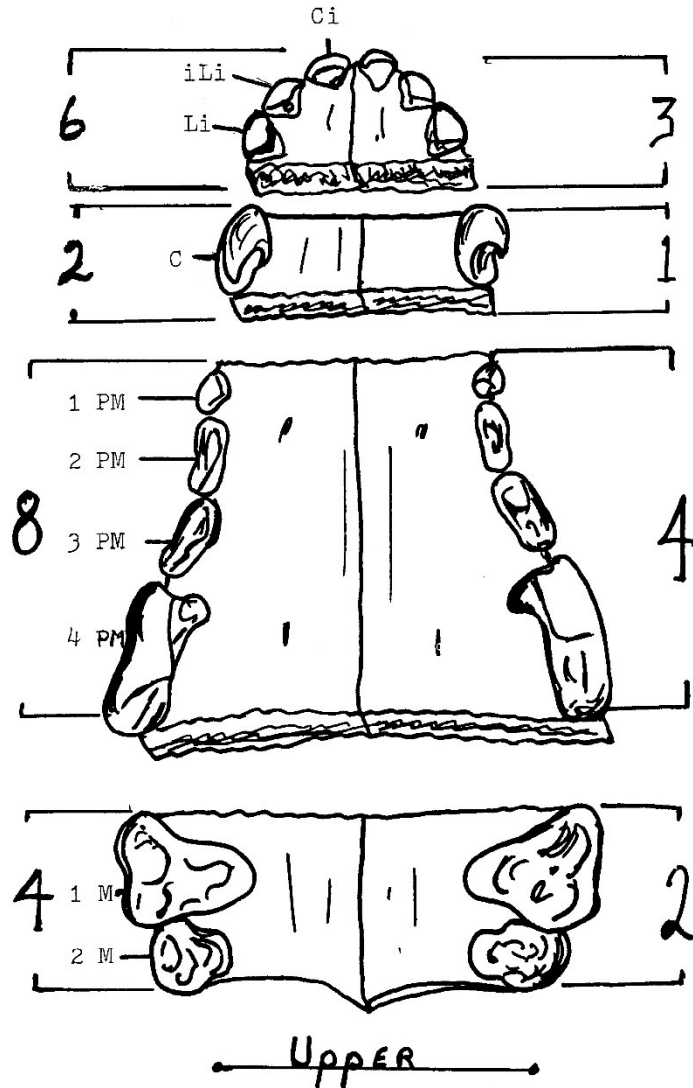


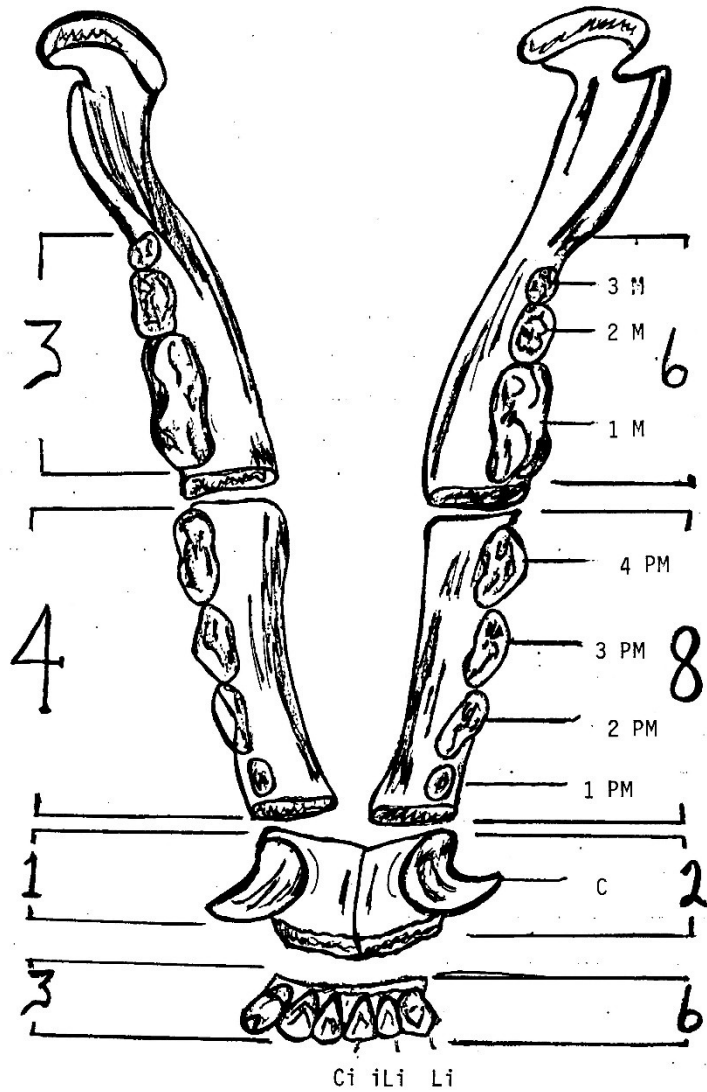
FIG 5 WRY



M - Molar
 PM - Premolar
 C - Canine

Li - Lateral incisor
 iLi - intermediate Lateral
 incisor
 Ci - Central Incisor

Dr. Peter Emily

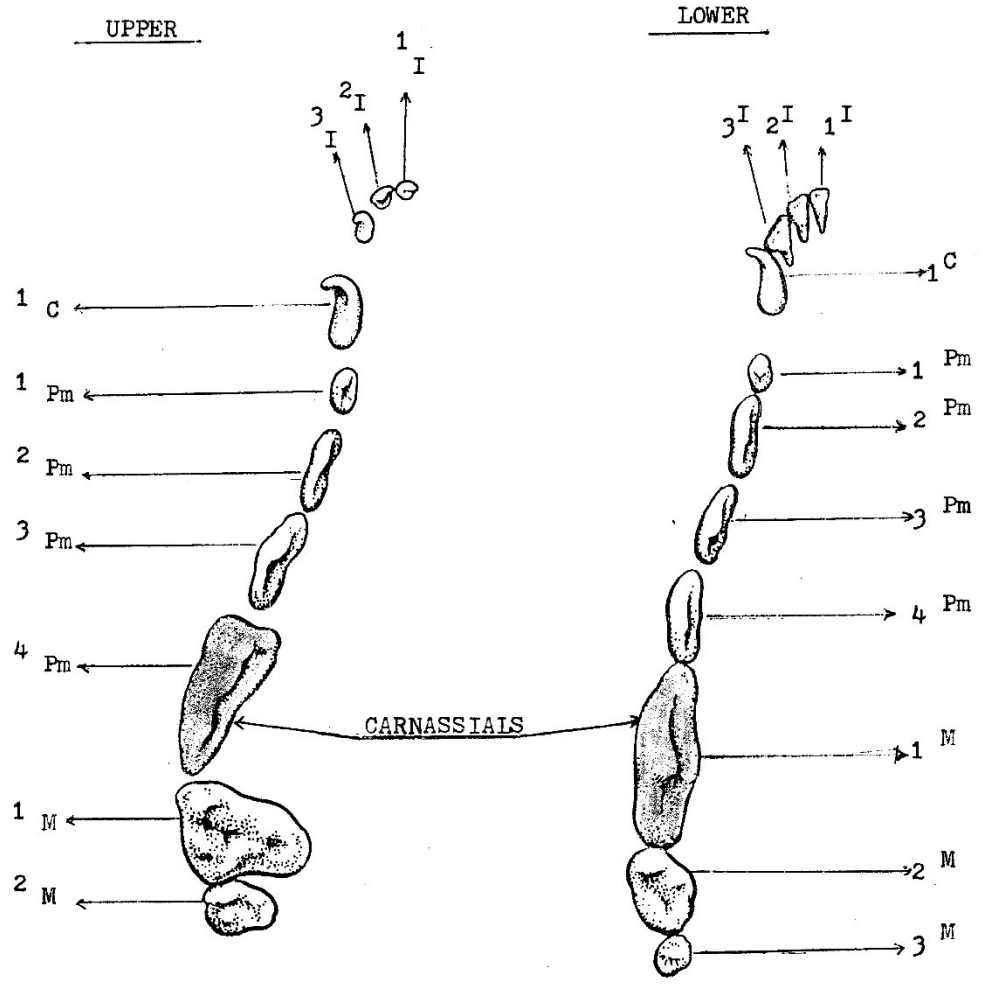


lower

M - Molar
 PM - Premolar
 C - Canine

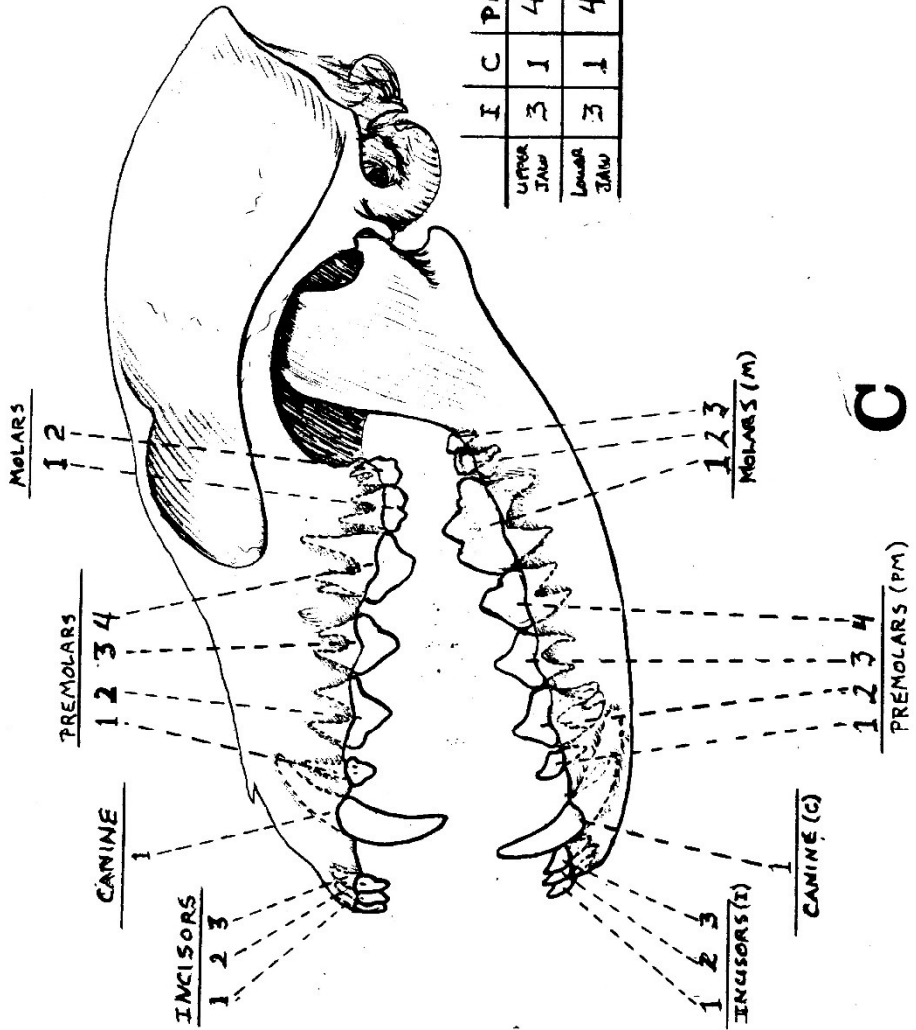
Ci - Central incisor
 iLi - intermediate Lateral
 incisor
 Li - Lateral incisor

Dr. Peter Emily

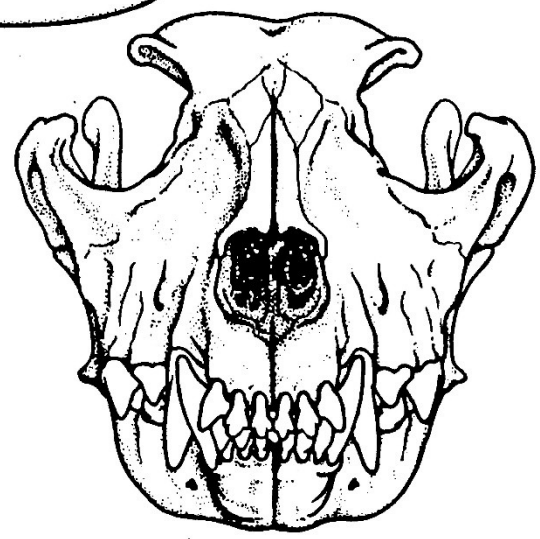
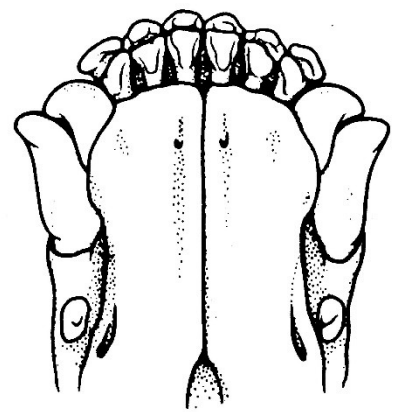
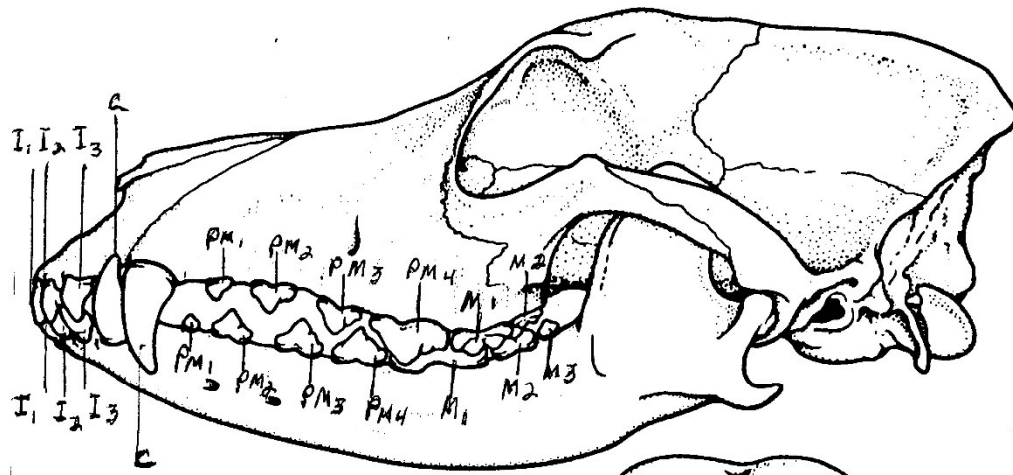


LEGEND

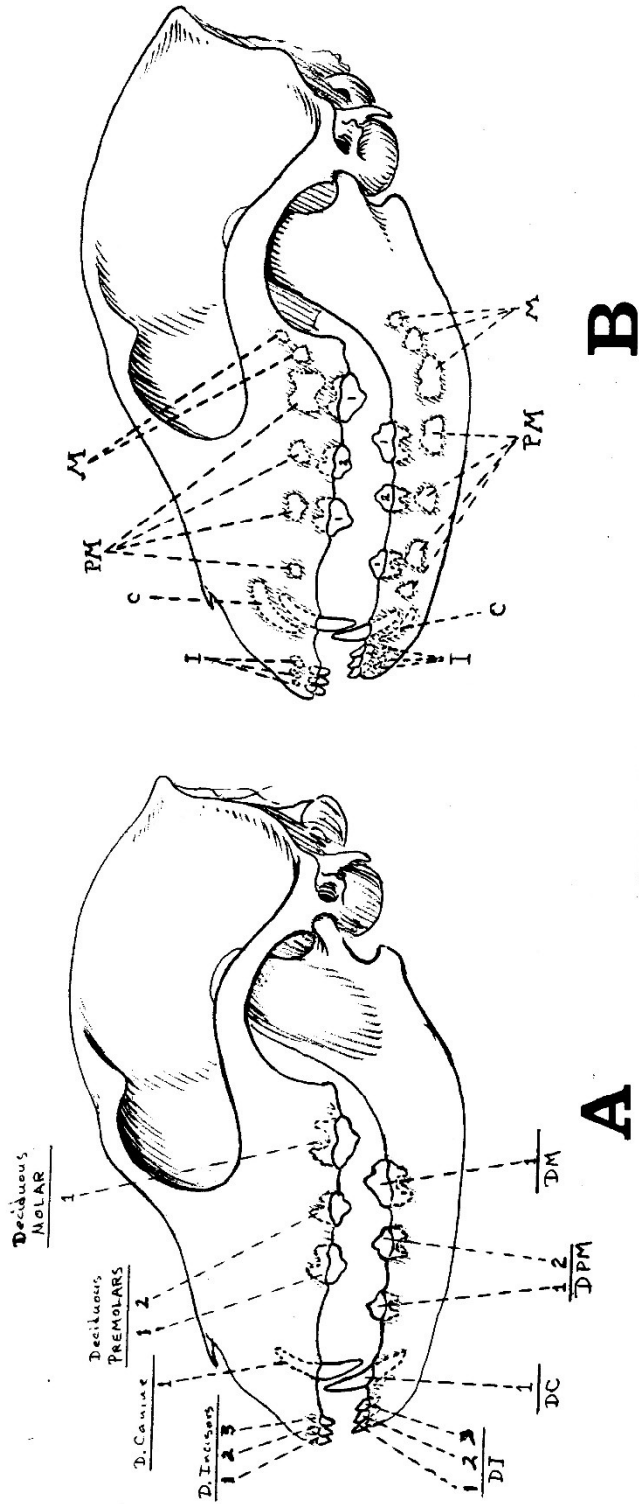
- C - Canine
- Pm - Premolar
- M - Molar
- I - Incisor



C



NORMAL



ERUPTION SEQUENCE

B

A